

CLINICAL PRESENTATION

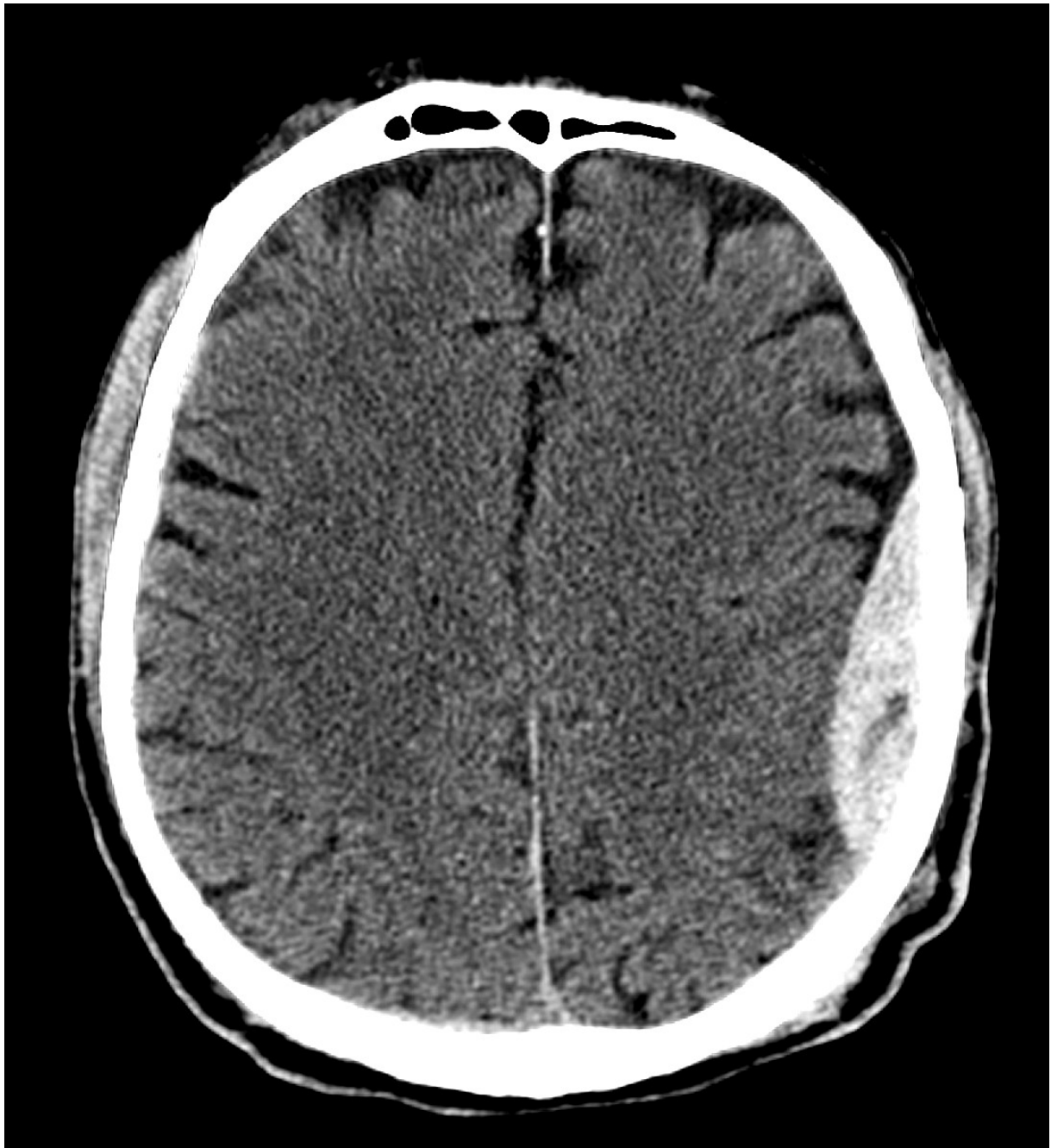Young male presents with a headache & brief loss of consciousness following a fall from a push bike.

What are the findings on the CT brain?

What features of mass effect would you look for?

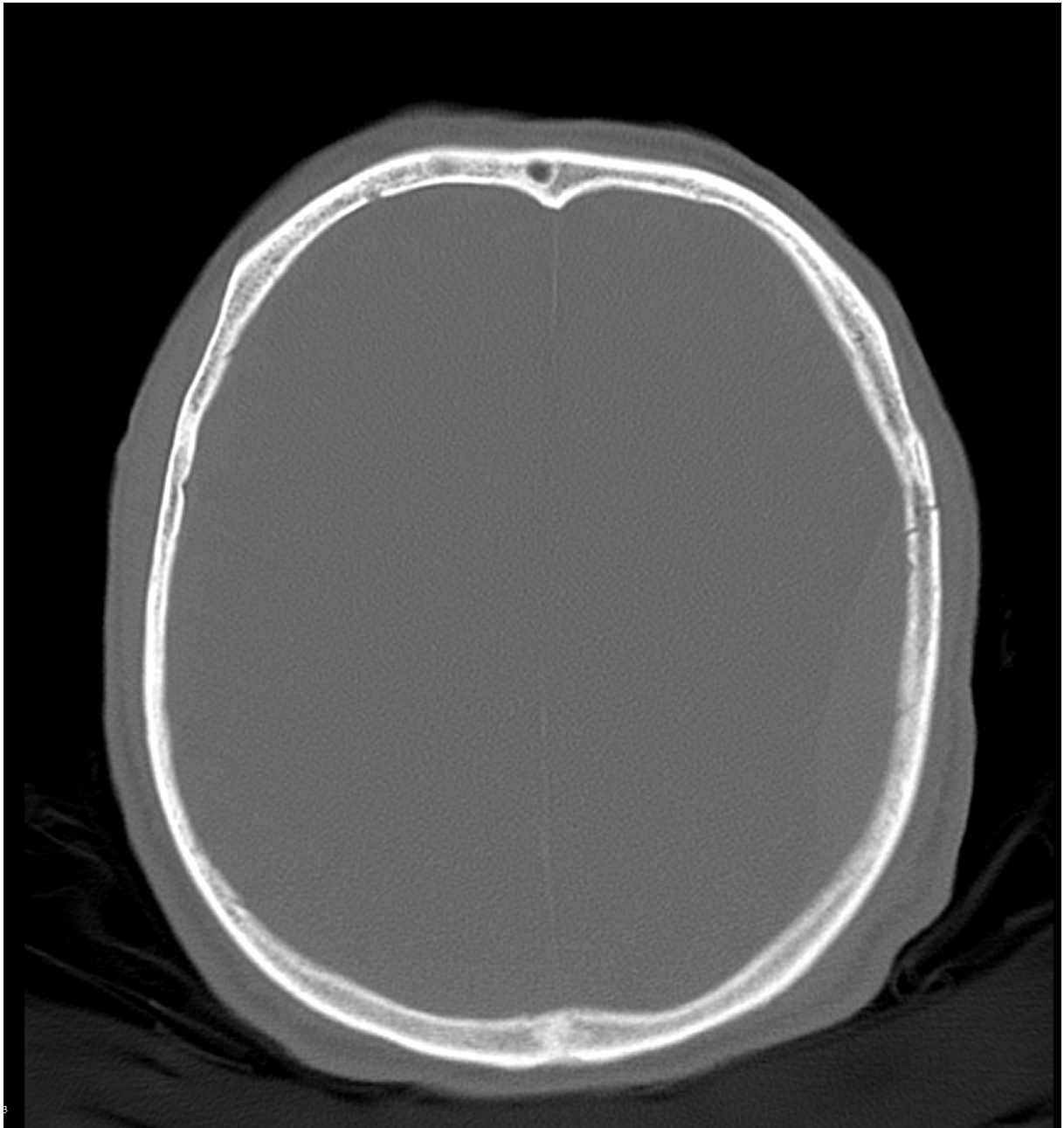IMAGES

CT BRAIN NON-CONTRAST – AXIAL SLICE, BRAIN WINDOW



Case courtesy of Assoc Prof Frank Gaillard
Radiopaedia.org <https://radiopaedia.org/>
From the case <https://radiopaedia.org/cases/19252> rID: 19252

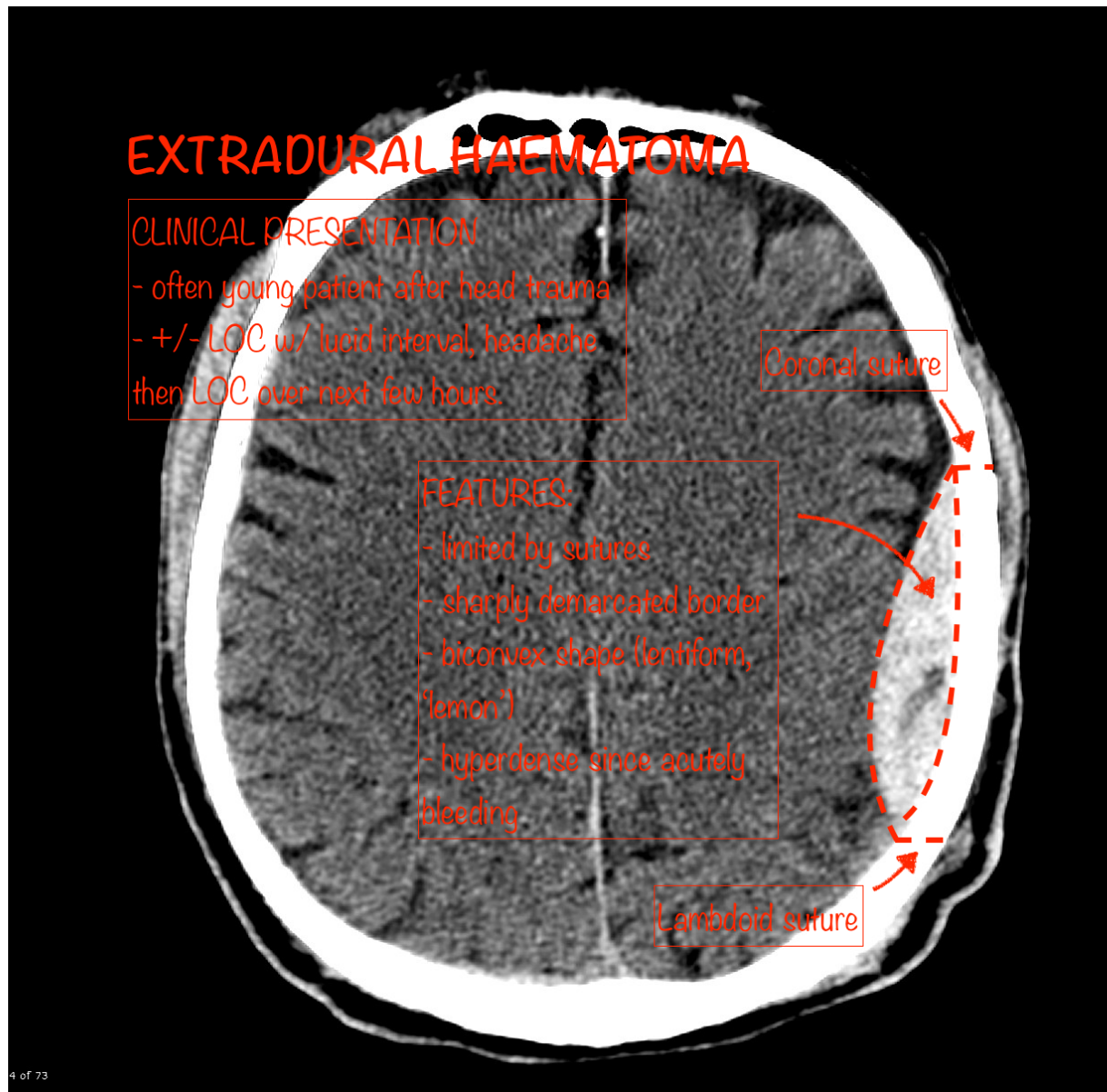
CT BRAIN NON-CONTRAST – AXIAL SLICE, BONE WINDOW



Case courtesy of Assoc Prof Frank Gaillard
Radiopaedia.org <https://radiopaedia.org/>
From the case <https://radiopaedia.org/cases/19252> rID: 19252

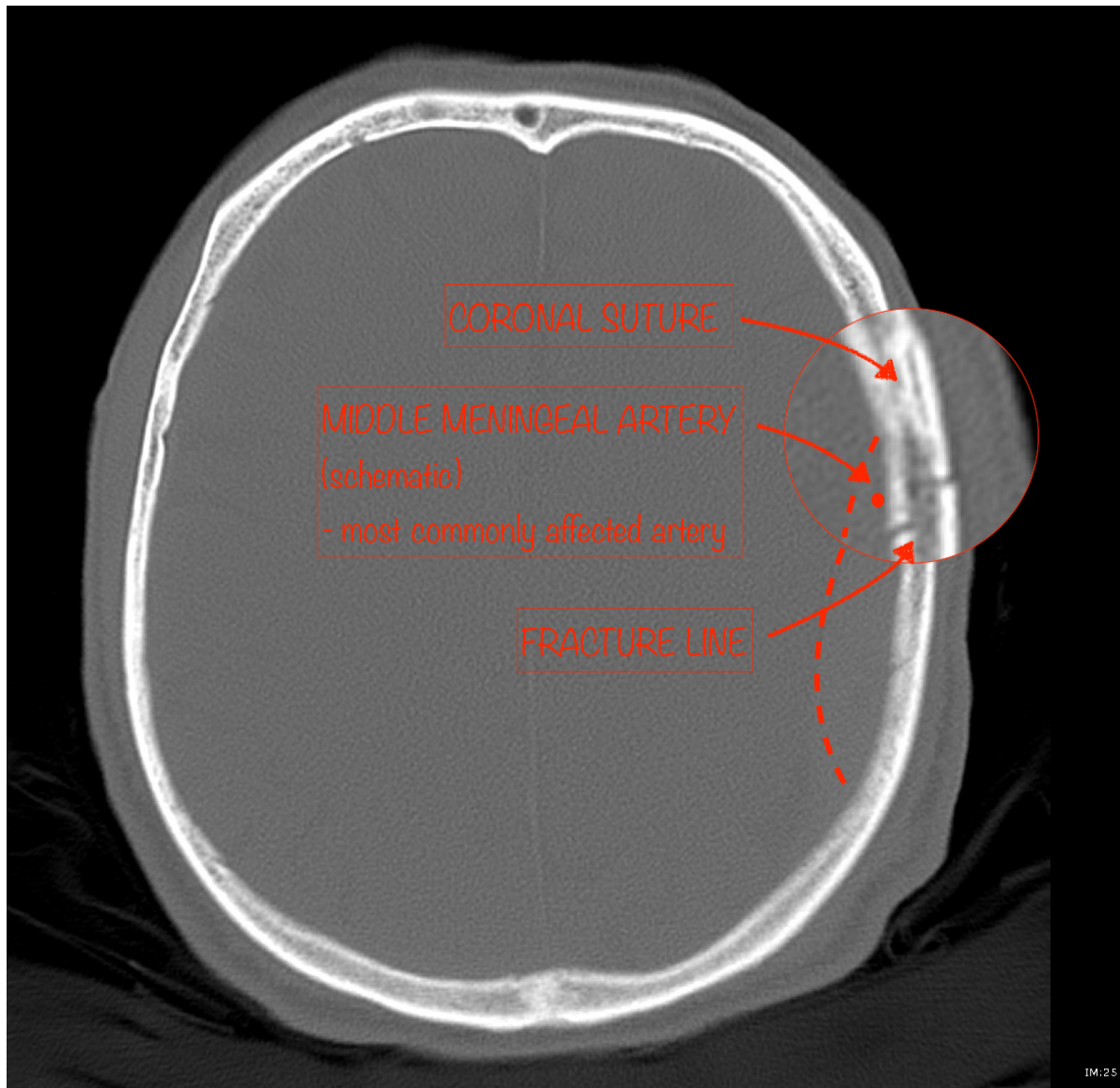
IMAGES ANNOTATED – EXTRADURAL HAEMATOMA

CASE – BRAIN WINDOW



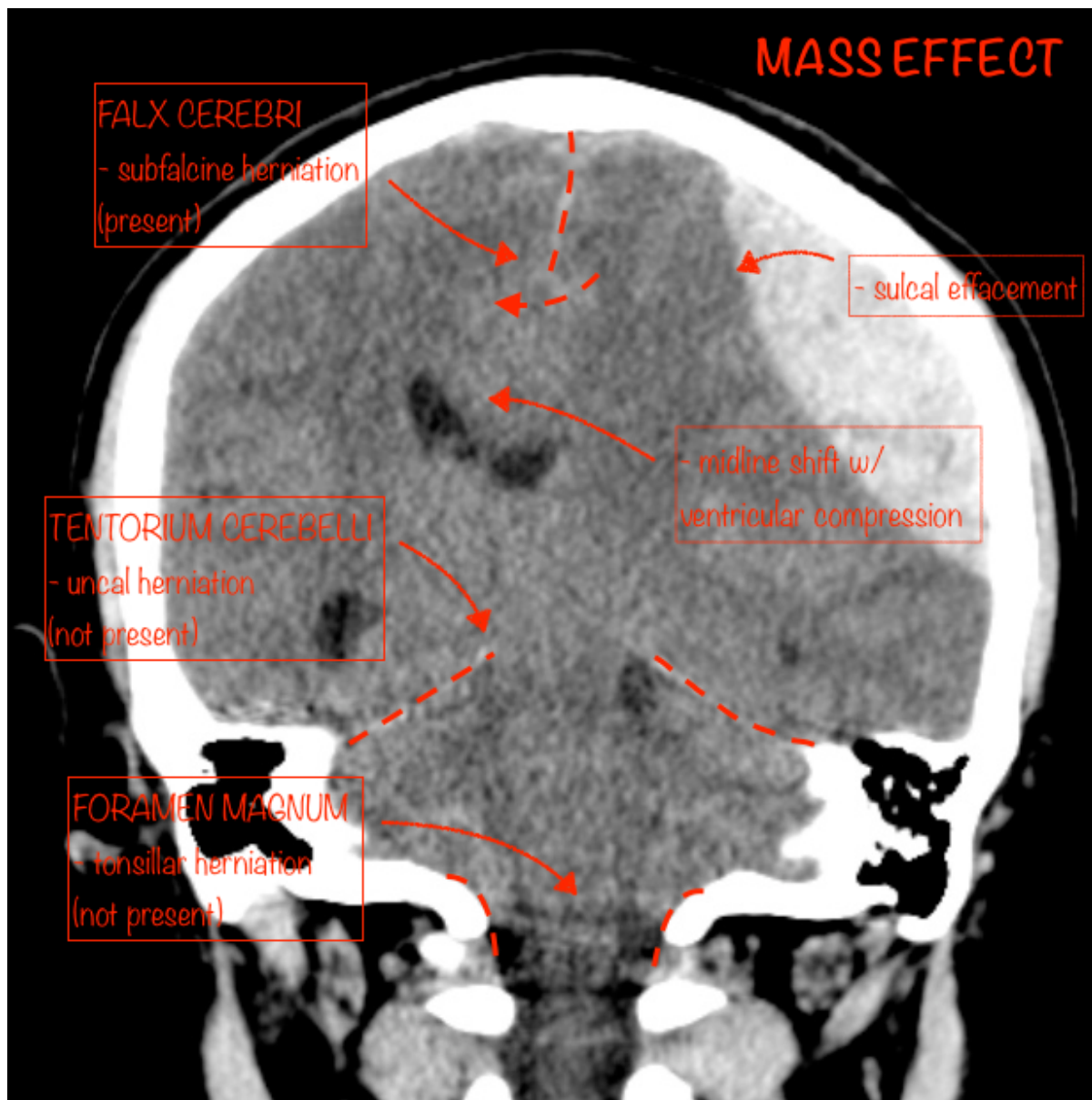
Case courtesy of Assoc Prof Frank Gaillard
Radiopaedia.org <https://radiopaedia.org/>
From the case <https://radiopaedia.org/cases/19252> rID: 19252

CASE – BONE WINDOW



Case courtesy of Assoc Prof Frank Gaillard
Radiopaedia.org <https://radiopaedia.org/>
From the case <https://radiopaedia.org/cases/19252> rID: 19252

EDH – FEATURES OF MASS EFFECT



Case courtesy of Dr David Cuete

Radiopaedia.org <https://radiopaedia.org/>

From the case <https://radiopaedia.org/cases/29440> rID: 29440

RESOURCES

- https://radiopaedia.org/articles/extradural-haemorrhage?lang=us#image_list_item_2293289
- <https://radiologyassistant.nl/neuroradiology/brain-anatomy>
- <https://oxfordmedicine-com.ezp.lib.unimelb.edu.au/view/10.1093/med/9780199216369.001.0001/med-9780199216369-chapter-0013>