

CLINICAL PRESENTATION

A 27-year-old male presents with severe colicky abdominal pain & microscopic haematuria on testing.

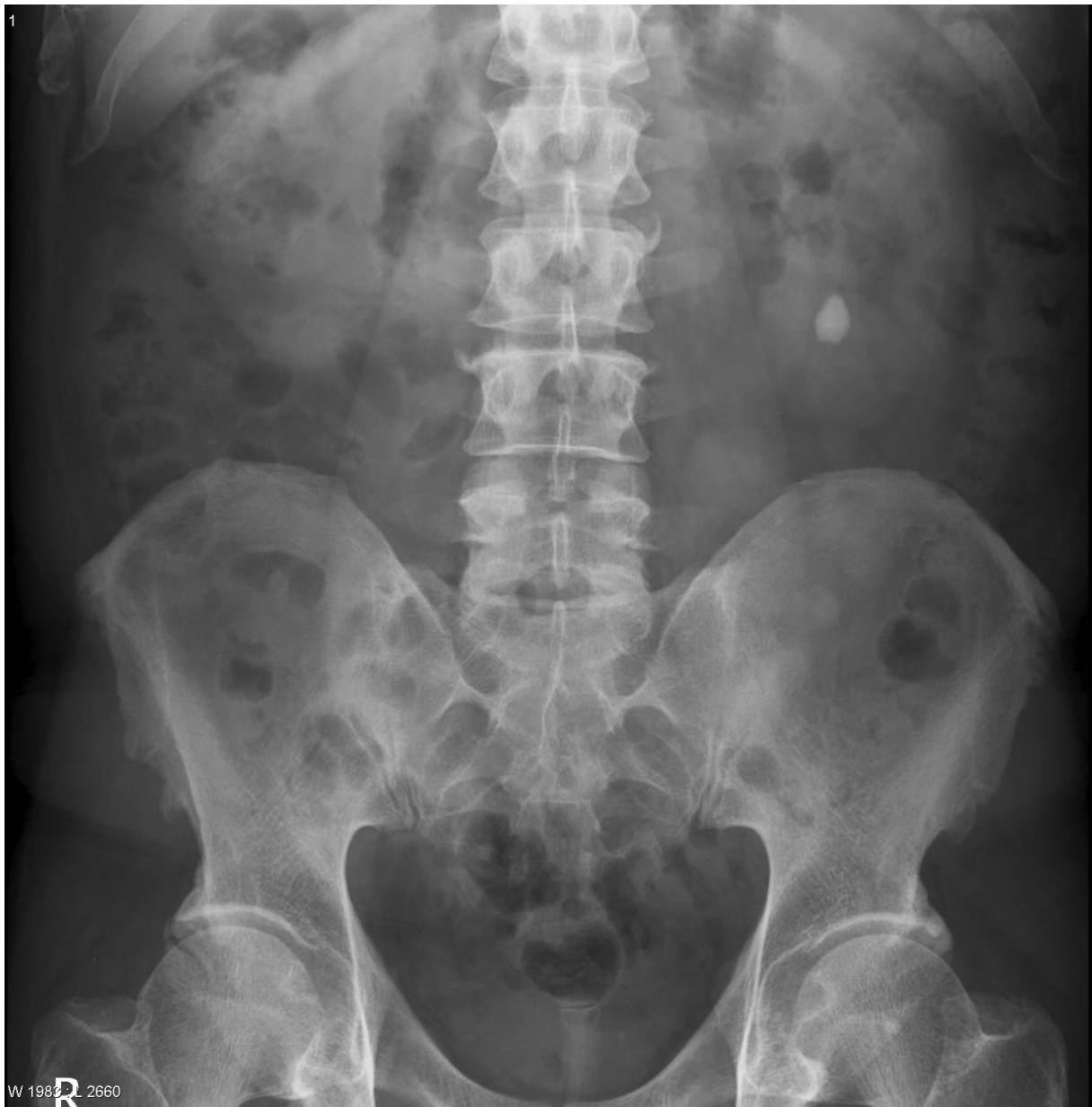What are the findings on the abdominal X-ray?

In most circumstances (e.g. not pregnant, not a child), what imaging would you order next?

What radiological features would indicate complication(s) of this condition?

IMAGES

ABDOMINAL X-RAY



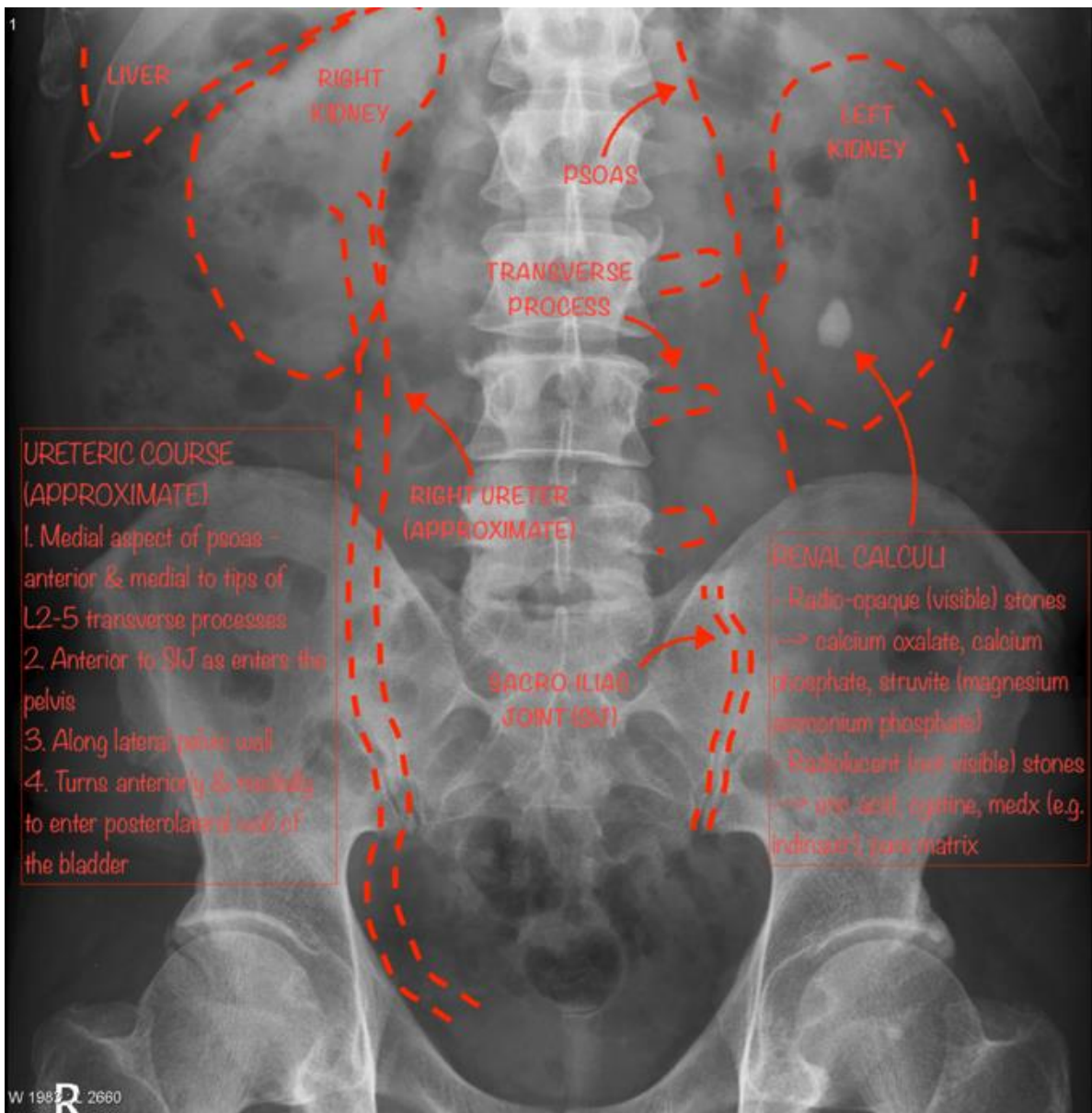
Case courtesy of Assoc Prof Frank Gaillard

Radiopaedia.org <https://radiopaedia.org/>

From the case <https://radiopaedia.org/cases/12555> rID: 12555

ANNOTATED IMAGES – RENAL CALCULUS (NEPHROLITHIASIS, UROLITHIASIS)

ABDOMINAL X-RAY – CASE



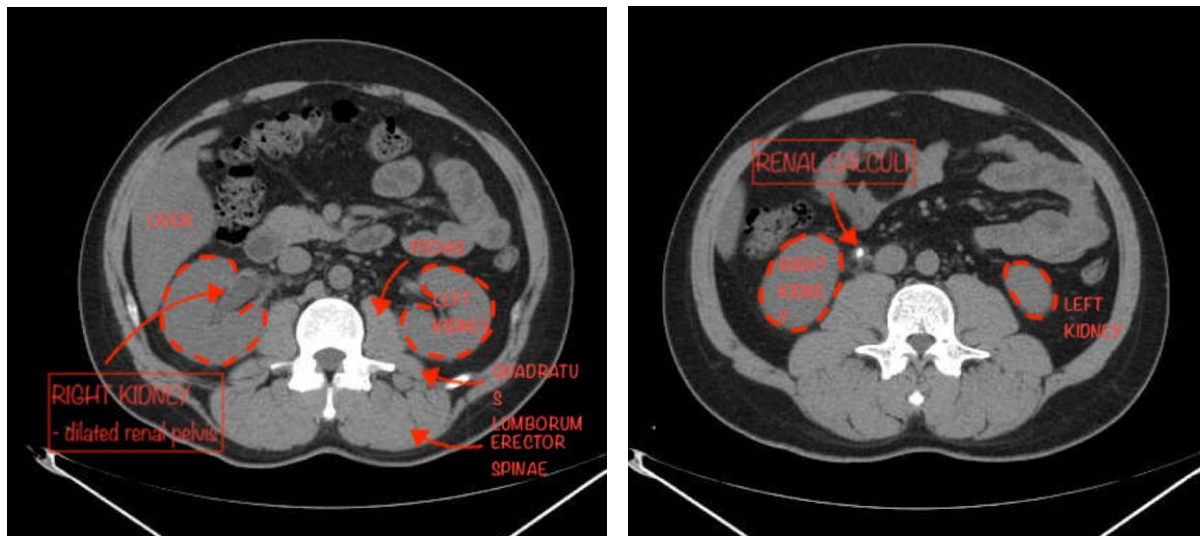
Case courtesy of Assoc Prof Frank Gaillard

Radiopaedia.org <https://radiopaedia.org/>

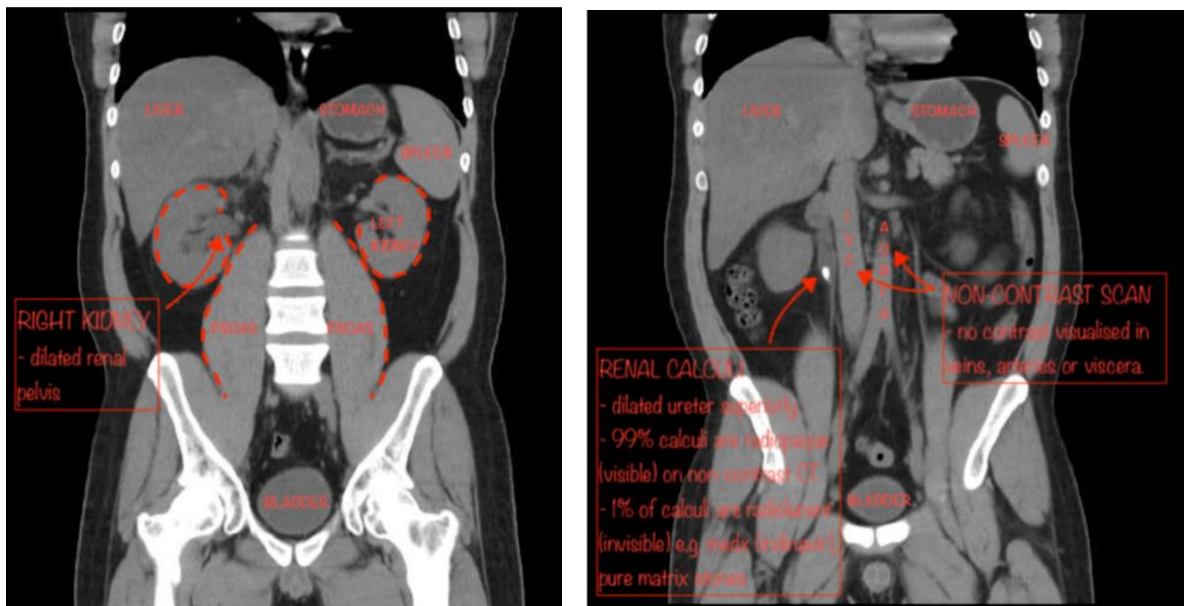
From the case <https://radiopaedia.org/cases/12555> rID: 12555

CTA NON-CONTRAST (CT KUB) – different patient

AXIAL



CORONAL



Case courtesy of Dr Muhammad Essam

Radiopaedia.org <https://radiopaedia.org/>

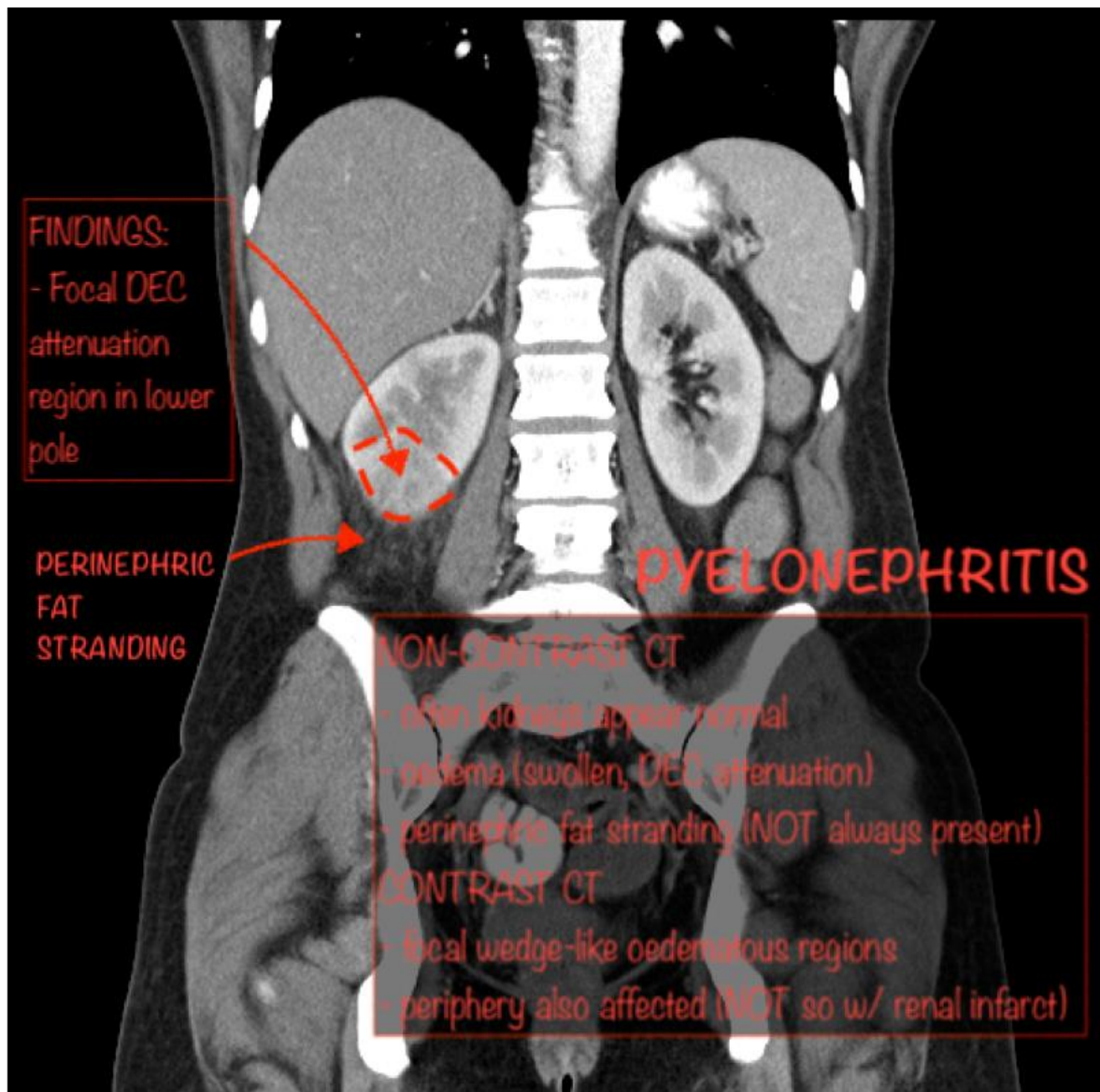
From the case <https://radiopaedia.org/cases/18328> rID: 18328

SOME NOTES ON US

- Frequently first Ix due to availability & lack of radiation, however, not as sensitive as CT.
- Often able to identify calculi (echogenic foci w/ acoustic shadowing) & complications such as hydronephrosis.
- Difficulty identifying small stones & those close to corticomedullary junction.
- Lack of radiation – good for pregnant women & younger patients.

COMPLICATIONS

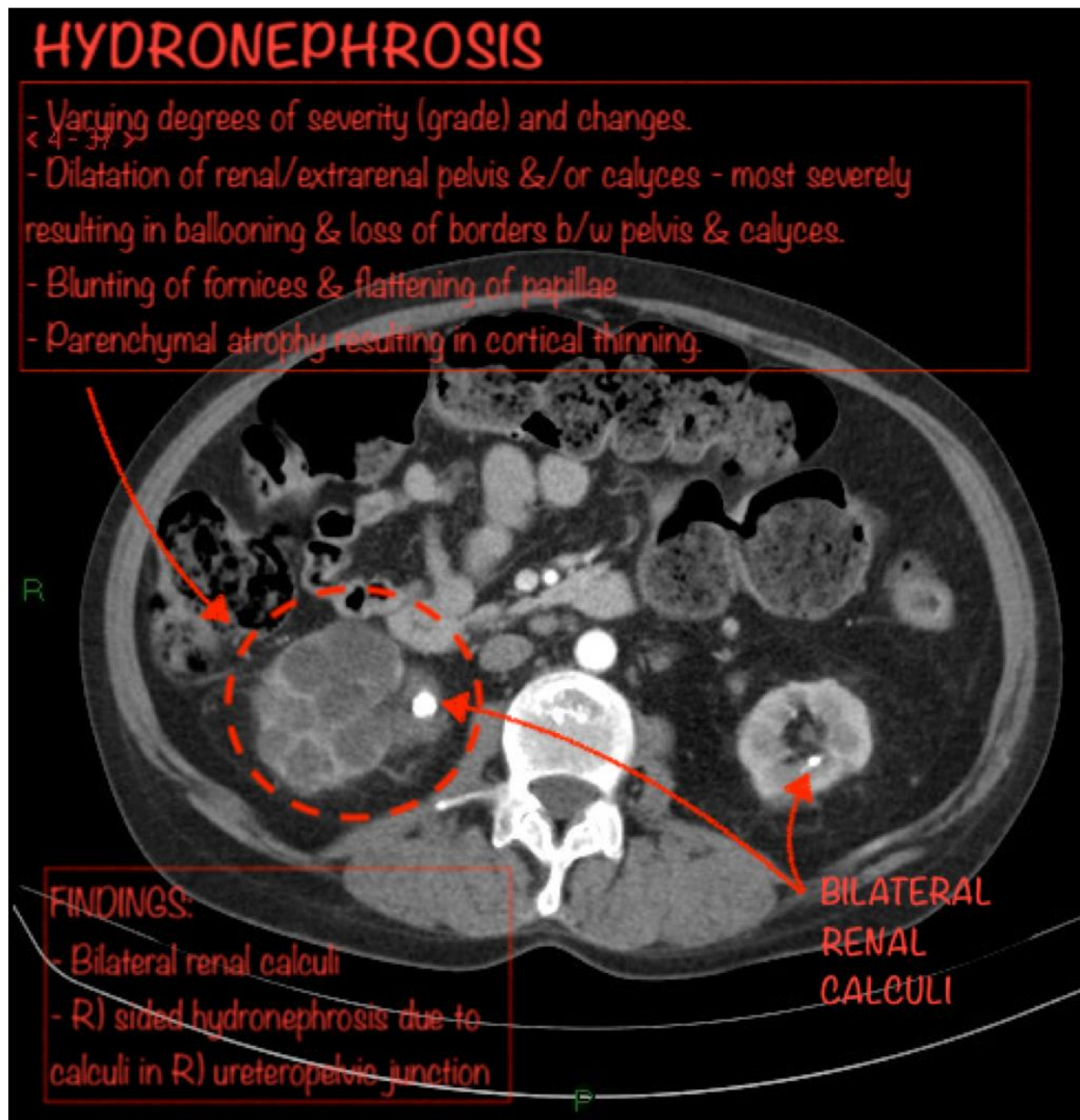
CTA + CONTRAST (PORTAL VENOUS PHASE) – CORONAL



Case courtesy of Dr Gagandeep Singh

Radiopaedia.org <https://radiopaedia.org/>

From the case <https://radiopaedia.org/cases/6628> rID: 6628



Case courtesy of Dr Sajoscha Sorrentino

Radiopaedia.org <https://radiopaedia.org/>

From the case <https://radiopaedia.org/cases/15679> rID: 15679

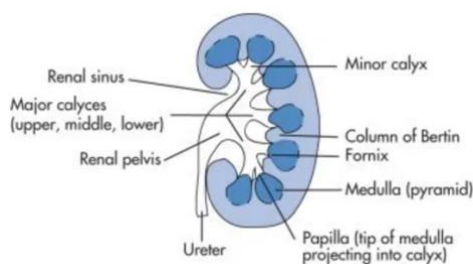


Image courtesy of <https://radiologykey.com/genitourinary-imaging-2/>

REFERENCES

<https://radiopaedia.org/articles/urolithiasis?lang=gb>

<https://radiopaedia.org/articles/pyelonephritis?lang=gb>

<https://radiopaedia.org/articles/acute-pyelonephritis-1?lang=gb>

<https://radiopaedia.org/articles/hydronephrosis-grading-1?lang=gb>

<https://radiopaedia.org/articles/abdominal-x-ray-an-approach-summary?lang=us>

<https://radiopaedia.org/articles/kidneys?lang=us>

<https://radiopaedia.org/articles/ureter?lang=us>

<https://oxfordmedicine->

[com.ezp.lib.unimelb.edu.au/view/10.1093/med/9780199216369.001.0001/med-9780199216369-](https://oxfordmedicine-com.ezp.lib.unimelb.edu.au/view/10.1093/med-9780199216369.001.0001/med-9780199216369-)

[chapter-0016#med-9780199216369-div1-021013](https://oxfordmedicine-com.ezp.lib.unimelb.edu.au/view/10.1093/med-9780199216369.001.0001/med-9780199216369-chapter-0016#med-9780199216369-div1-021013)

<https://bestpractice-bmj-com.ezp.lib.unimelb.edu.au/topics/en-gb/225>