

CASE

A 62 year old female presents with abdominal pain and 3 days of constipation.

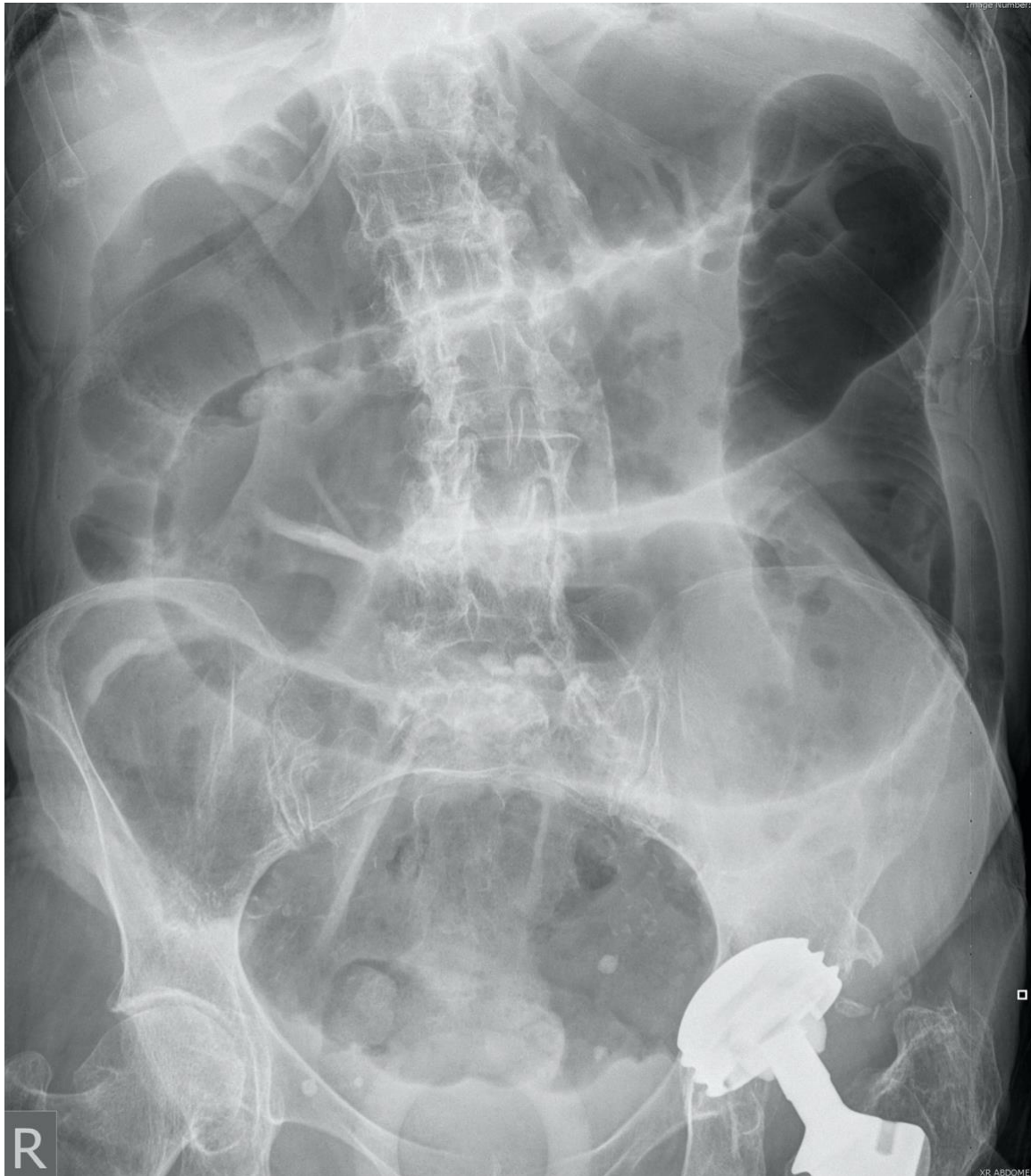What are the findings on abdominal X-ray?

What imaging would you order next? And, what additional information would this imaging provide?

What complications of this condition would you be looking for radiologically?

IMAGES

ABDOMINAL X-RAY



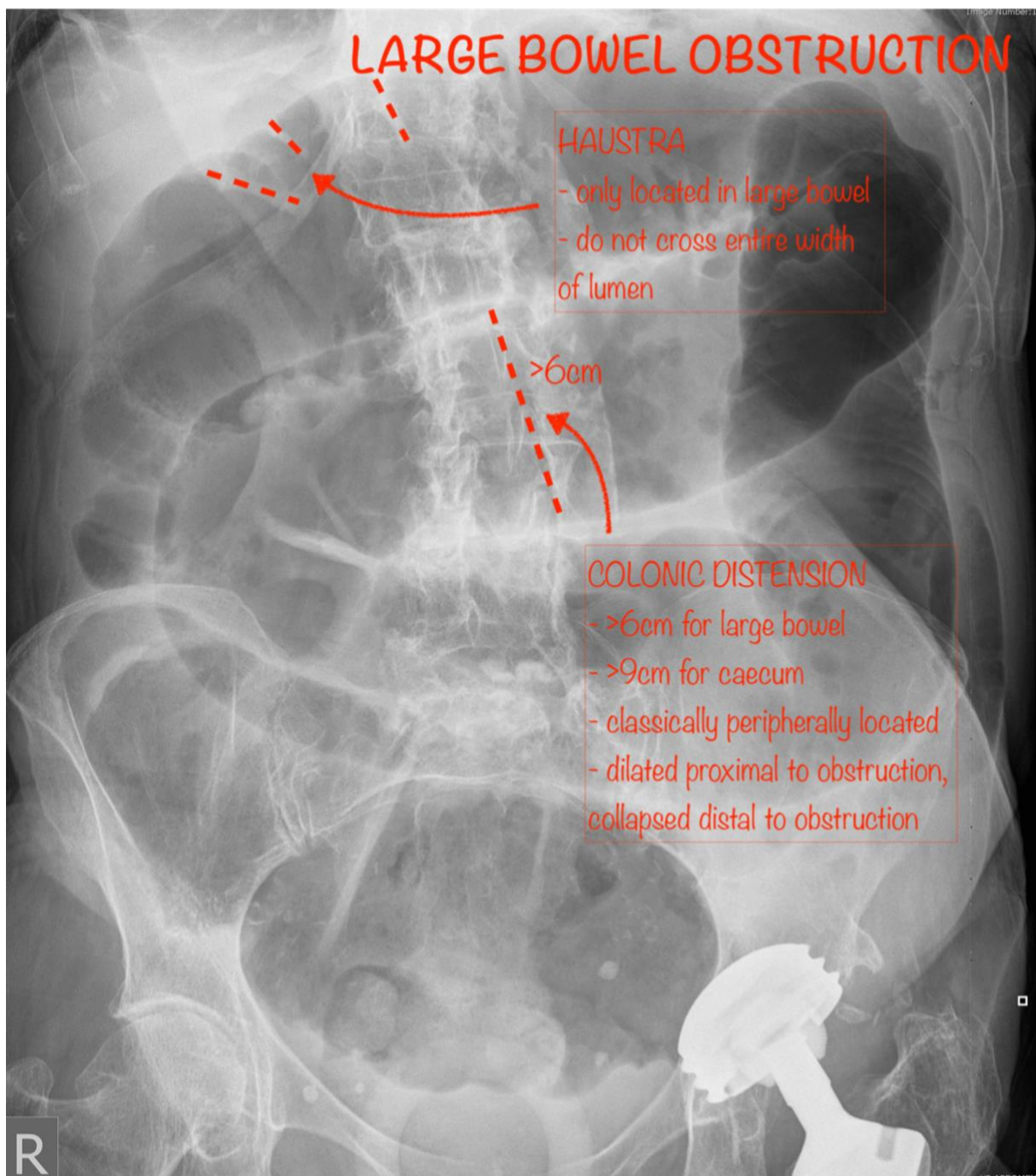
Case courtesy of Dr Ian Bickle

Radiopaedia.org <https://radiopaedia.org/>

From the case <https://radiopaedia.org/cases/50391> rID: 50391

ANNOTATED IMAGES – BOWEL OBSTRUCTION

ABDOMINAL X-RAY – CASE (LARGE BOWEL OBSTRUCTION)



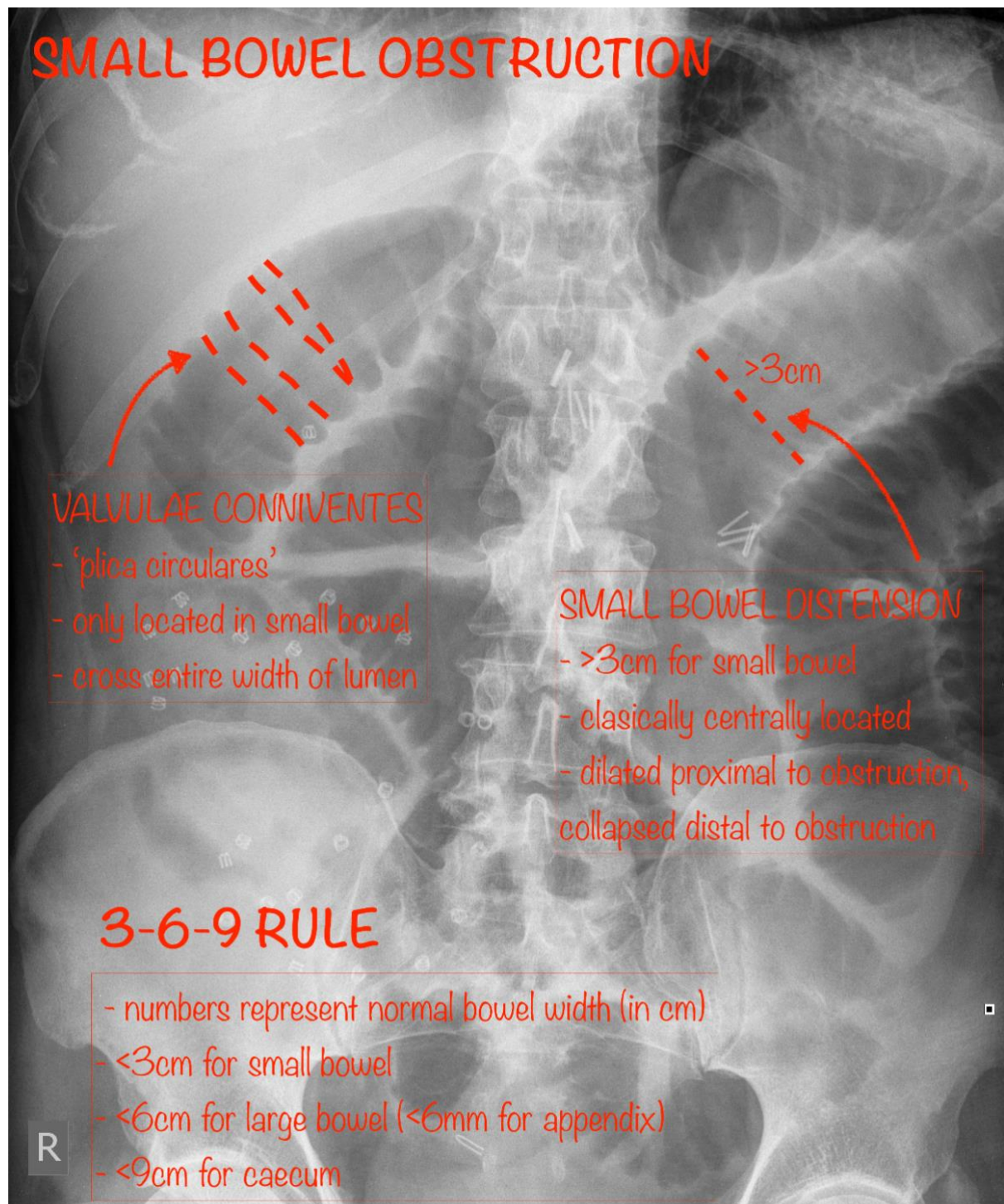
Case courtesy of Dr Ian Bickle

Radiopaedia.org <https://radiopaedia.org/>

From the case <https://radiopaedia.org/cases/50391> rID: 50391

ABDOMINAL X-RAY – SMALL BOWEL OBSTRUCTION

- AXR is only 50-60% Sn for SBO.



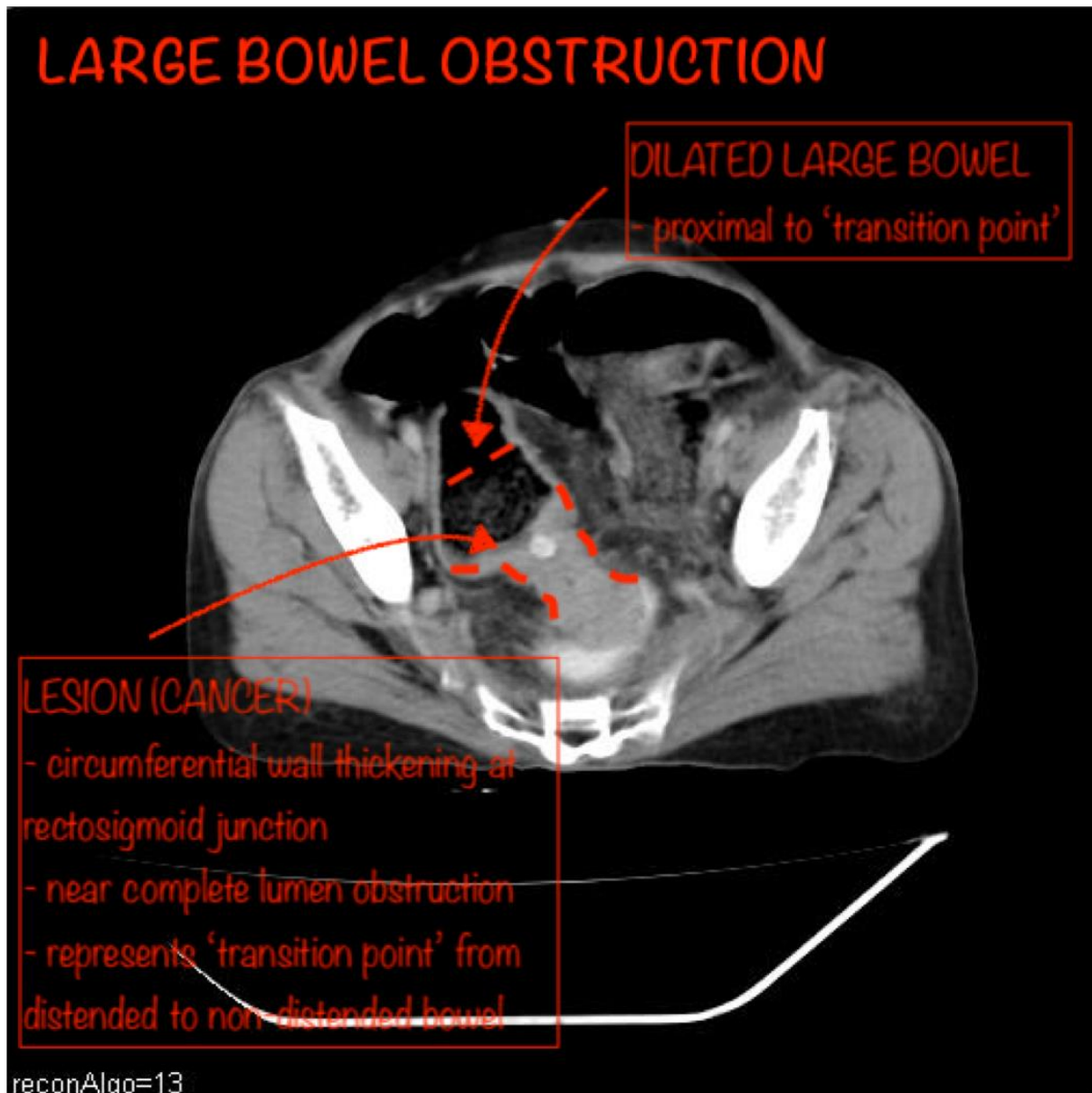
Case courtesy of Dr Ian Bickle

Radiopaedia.org <https://radiopaedia.org/>

From the case <https://radiopaedia.org/cases/34633> rID: 34633

CTA W/ CONTRAST – AXIAL

- CT in this setting usually confirms Dx, and identifies location of obstruction and aetiology (in most cases)

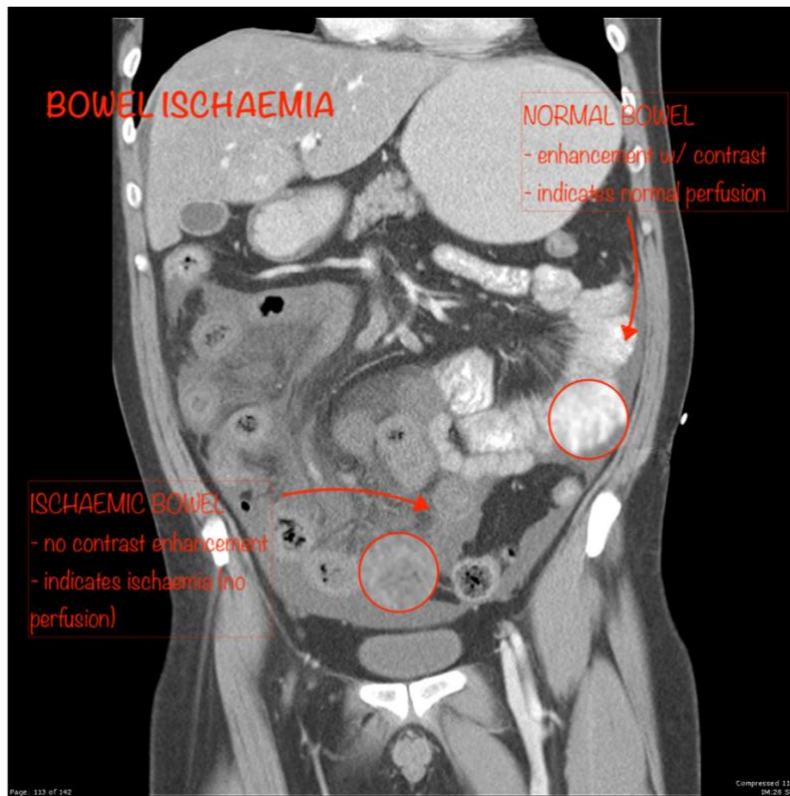


Case courtesy of Dr Ayush Goel

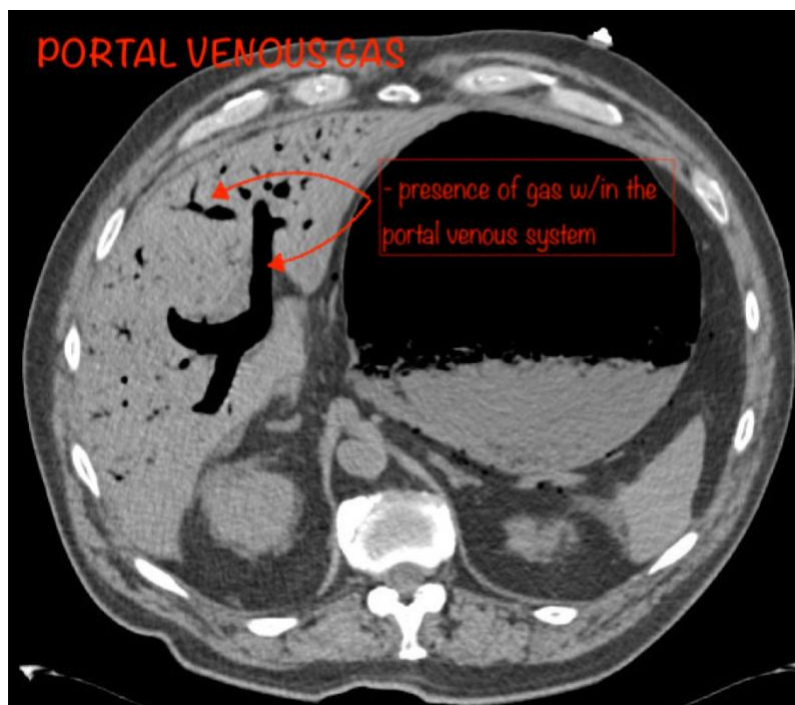
Radiopaedia.org <https://radiopaedia.org/>

From the case <https://radiopaedia.org/cases/34701> rID: 34701

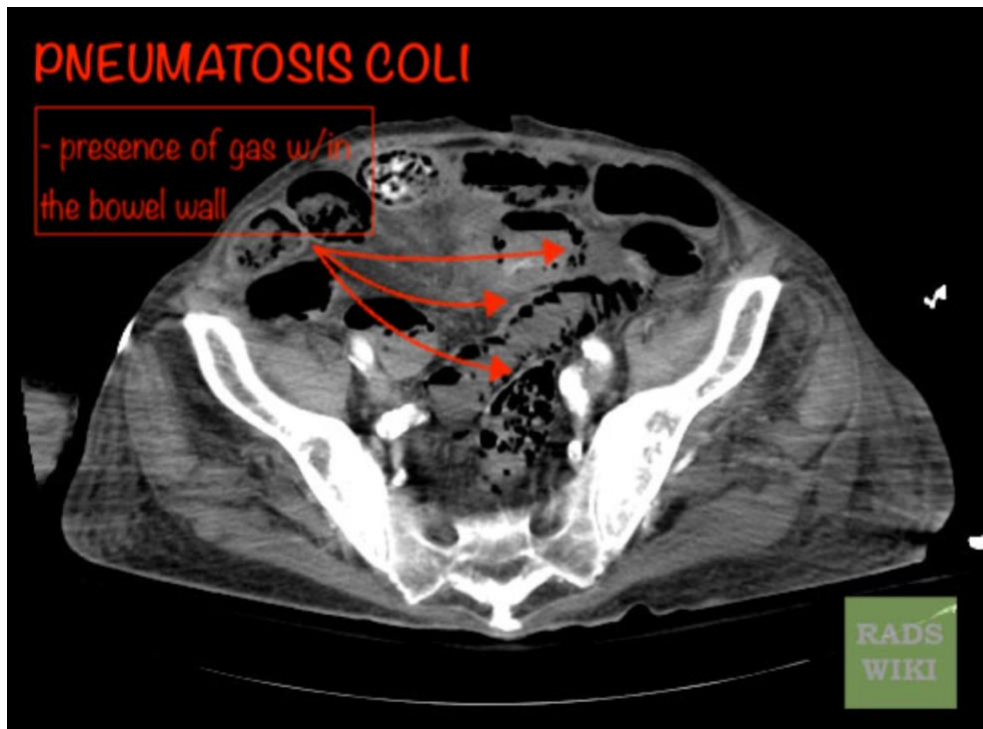
COMPLICATIONS



Case courtesy of Assoc Prof Frank Gaillard
Radiopaedia.org <https://radiopaedia.org/>
From the case <https://radiopaedia.org/cases/18463> rID: 18463



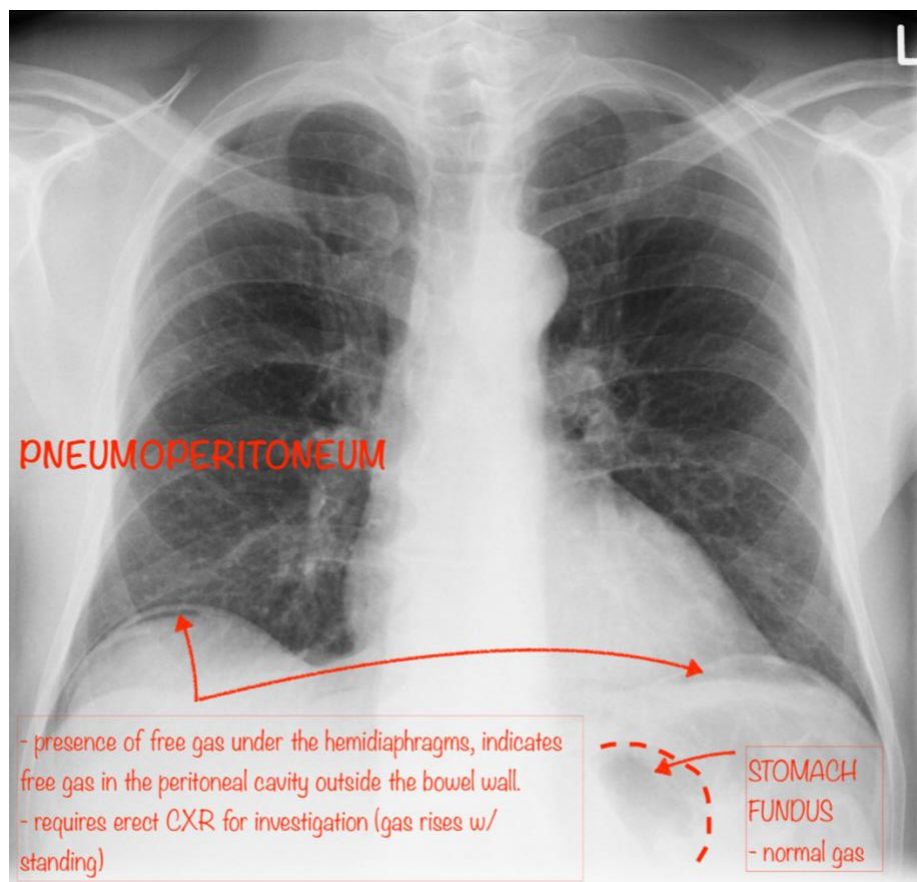
Case courtesy of Assoc Prof Frank Gaillard
Radiopaedia.org <https://radiopaedia.org/>
From the case <https://radiopaedia.org/cases/2654> rID: 2654



Case courtesy of RadsWiki

Radiopaedia.org <https://radiopaedia.org/>

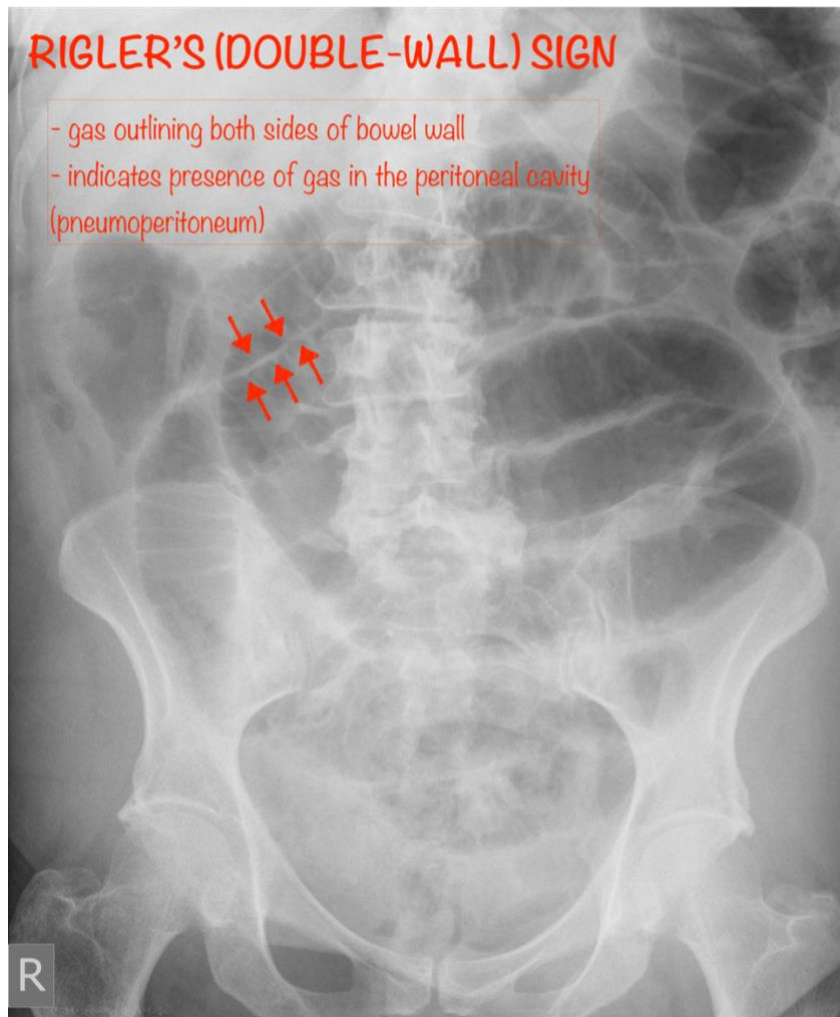
From the case <https://radiopaedia.org/cases/11553> rID: 11553



Case courtesy of Dr Sajoscha Sorrentino

Radiopaedia.org <https://radiopaedia.org/>

From the case <https://radiopaedia.org/cases/14866> rID: 14866



Case courtesy of Dr Jeremy Jones

Radiopaedia.org <https://radiopaedia.org/>

From the case <https://radiopaedia.org/cases/4846> rID: 4846

REFERENCES

<https://radiopaedia.org/articles/bowel-obstruction?lang=gb>

<https://radiopaedia.org/articles/3-6-9-rule-bowel?lang=gb>

https://radiopaedia.org/articles/small-bowel-obstruction?lang=gb#image_list_item_11381359

<https://radiopaedia.org/articles/large-bowel-obstruction?lang=gb>

<https://radiopaedia.org/articles/rigler-sign-bowel?lang=gb>

<https://radiopaedia.org/articles/pneumatosis-coli?lang=gb>

<https://oxfordmedicine->

[com.ezp.lib.unimelb.edu.au/view/10.1093/med/9780199216369.001.0001/med-9780199216369-chapter-0023#med-9780199216369-div1-030017](https://oxfordmedicine-com.ezp.lib.unimelb.edu.au/view/10.1093/med/9780199216369.001.0001/med-9780199216369-chapter-0023#med-9780199216369-div1-030017)