

CASE

45 year old male with hypertension presents to the ED with a fever and cough. No recent travel history or sick contacts.

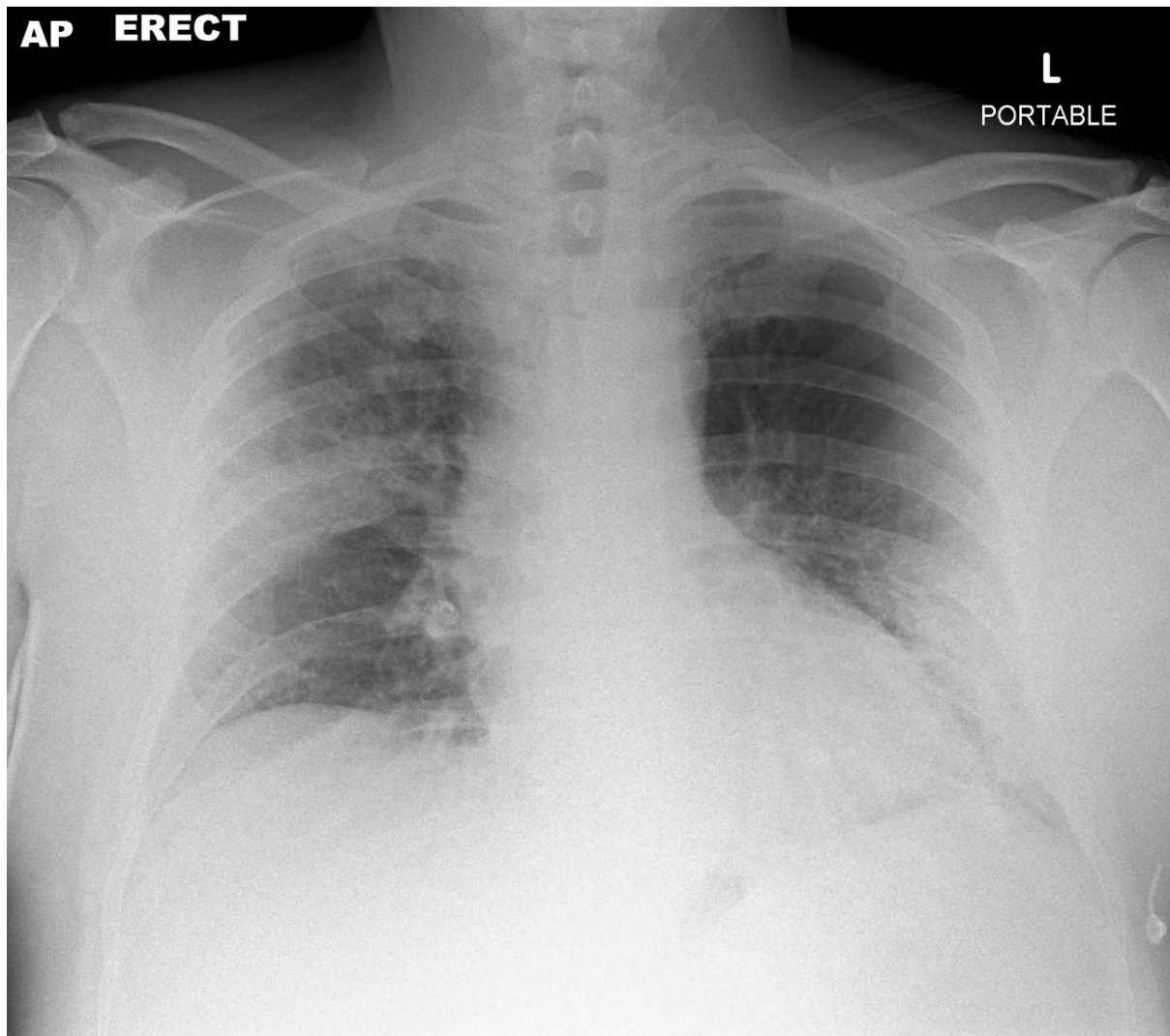
What are the findings on the CXR?

In the current context (Apr 2020), how would you diagnose the most important differential for this presentation (non-radiological & radiological)?

What precautions should be considered when assessing & imaging this patient?

IMAGES

AP ERECT PORTABLE CXR



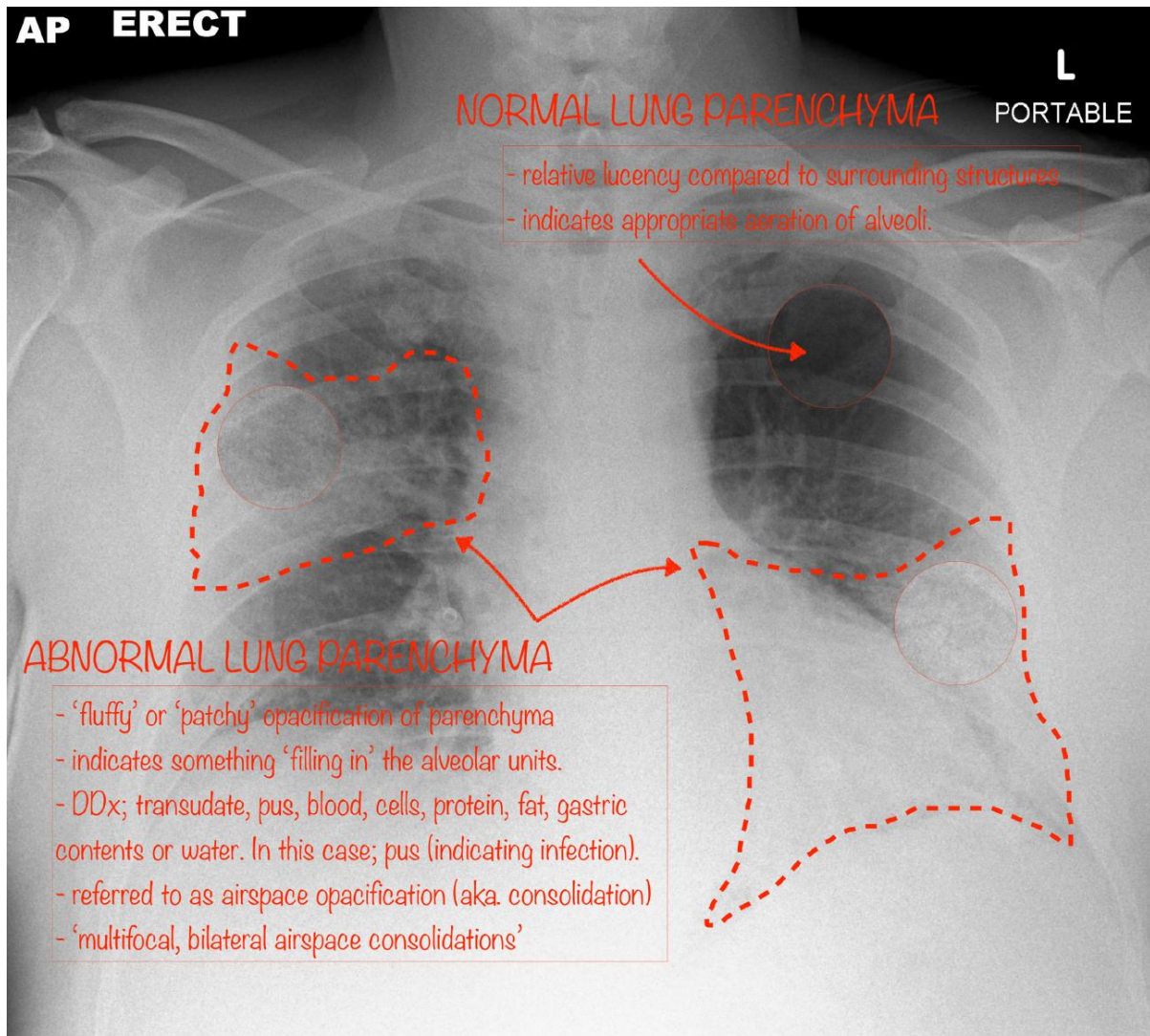
Case courtesy of Dr Derek Smith

Radiopaedia.org <https://radiopaedia.org/>

From the case <https://radiopaedia.org/cases/75251> rID: 75251

ANNOTATED IMAGES – COVID-19

ANNOTATED AP ERECT PORTABLE CXR – COVID-19

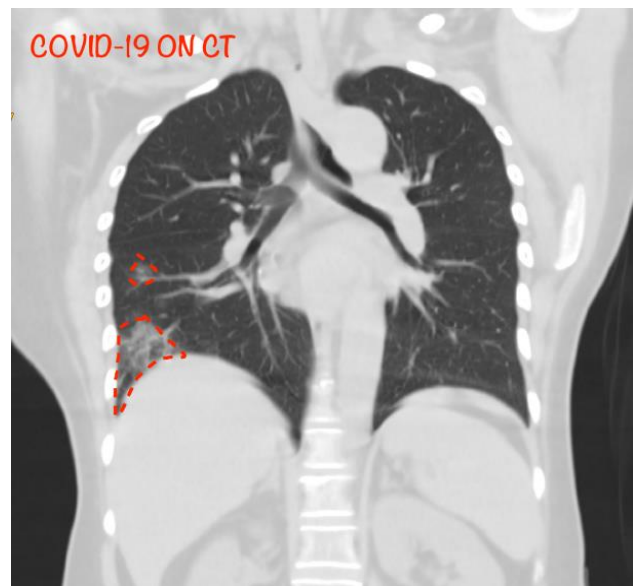
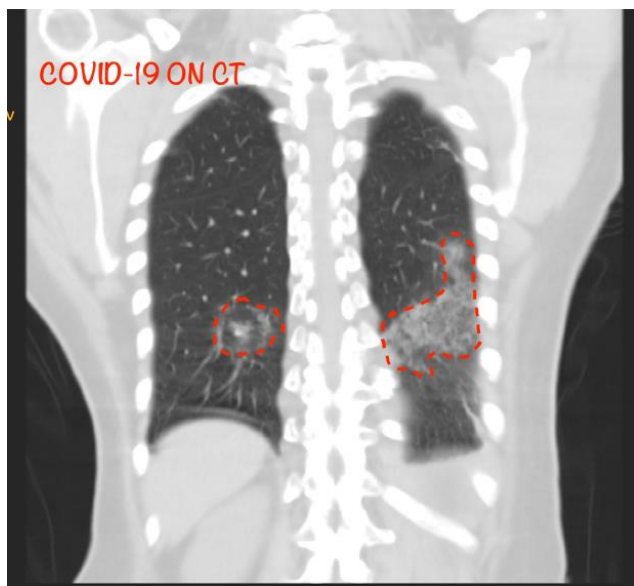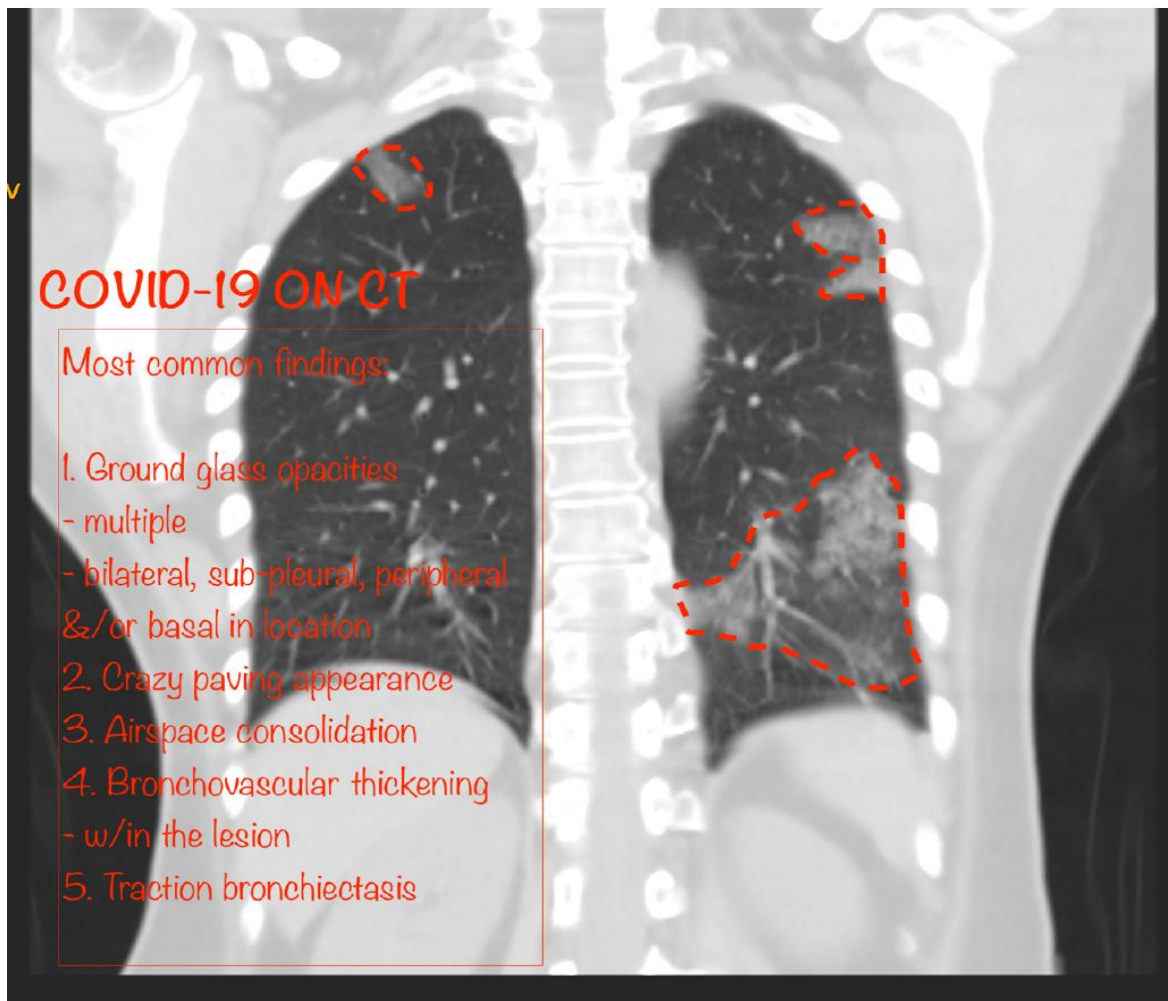


Case courtesy of Dr Derek Smith

Radiopaedia.org <https://radiopaedia.org/>

From the case <https://radiopaedia.org/cases/75251> rID: 75251

CORONAL CT CHEST – COVID-19 (from a different patient to the CXR)



Case courtesy of Dr Sam Chong Keng Sang
Radiopaedia.org <https://radiopaedia.org/>
From the case <https://radiopaedia.org/cases/73893> rID: 73893

MOST COMMON COVID-19 FINDINGS ON CT

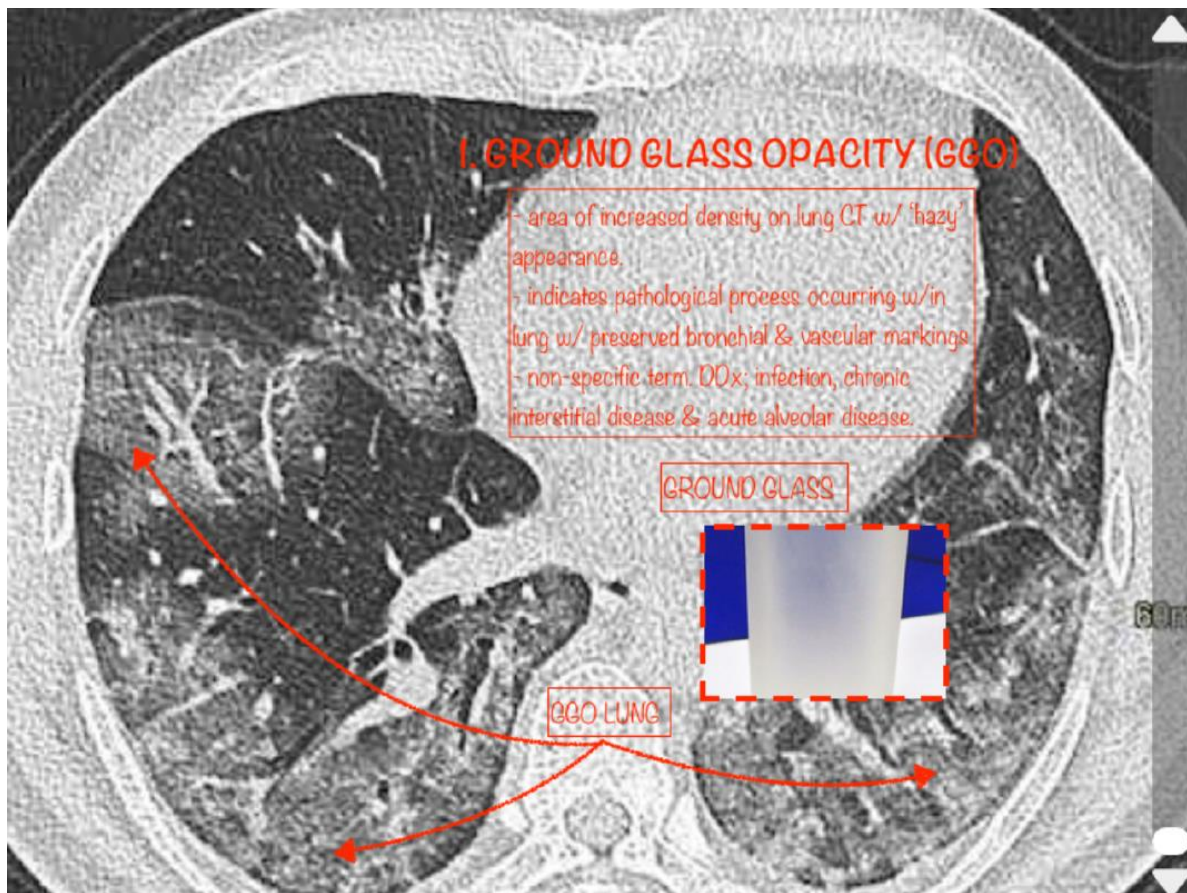
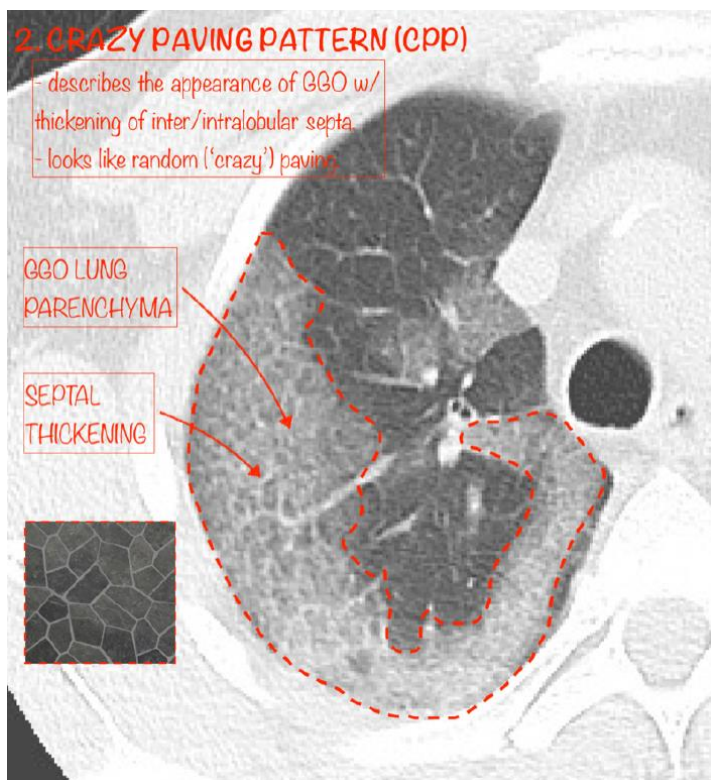


Photo courtesy of The Radiology Assistant

<https://radiologyassistant.nl/chest/lk-jg-1#chest-radiograph>



Case courtesy of Dr Bruno Di Muzio
Radiopaedia.org

<https://radiopaedia.org/>

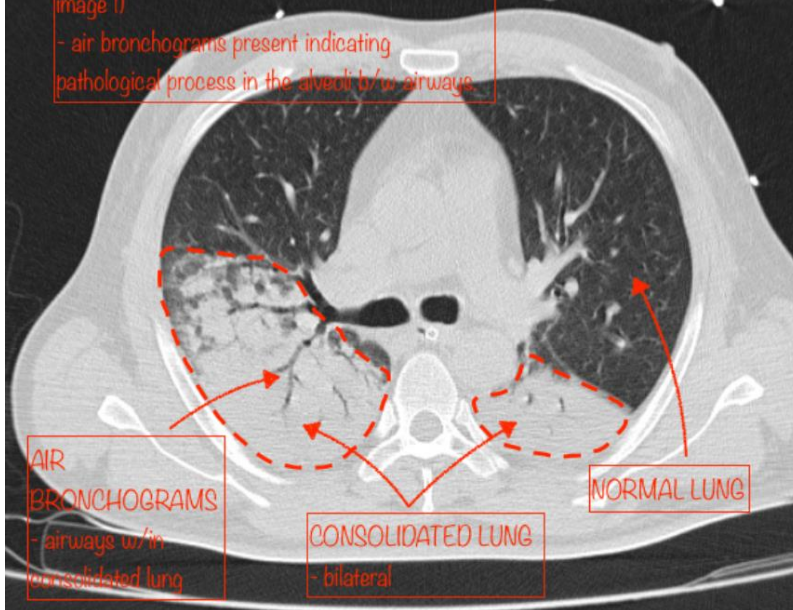
From the case

<https://radiopaedia.org/cases/63668>

rID: 63668

3. AIRSPACE CONSOLIDATION

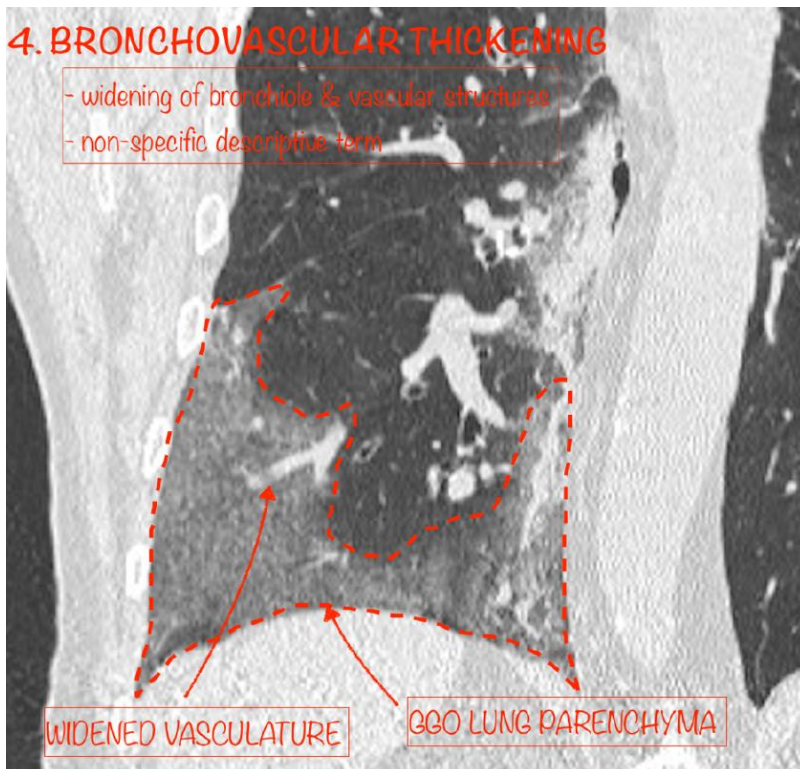
- 'filling in' of alveolar units (as shown on CXR image !)
- air bronchograms present indicating pathological process in the alveoli b/w airways



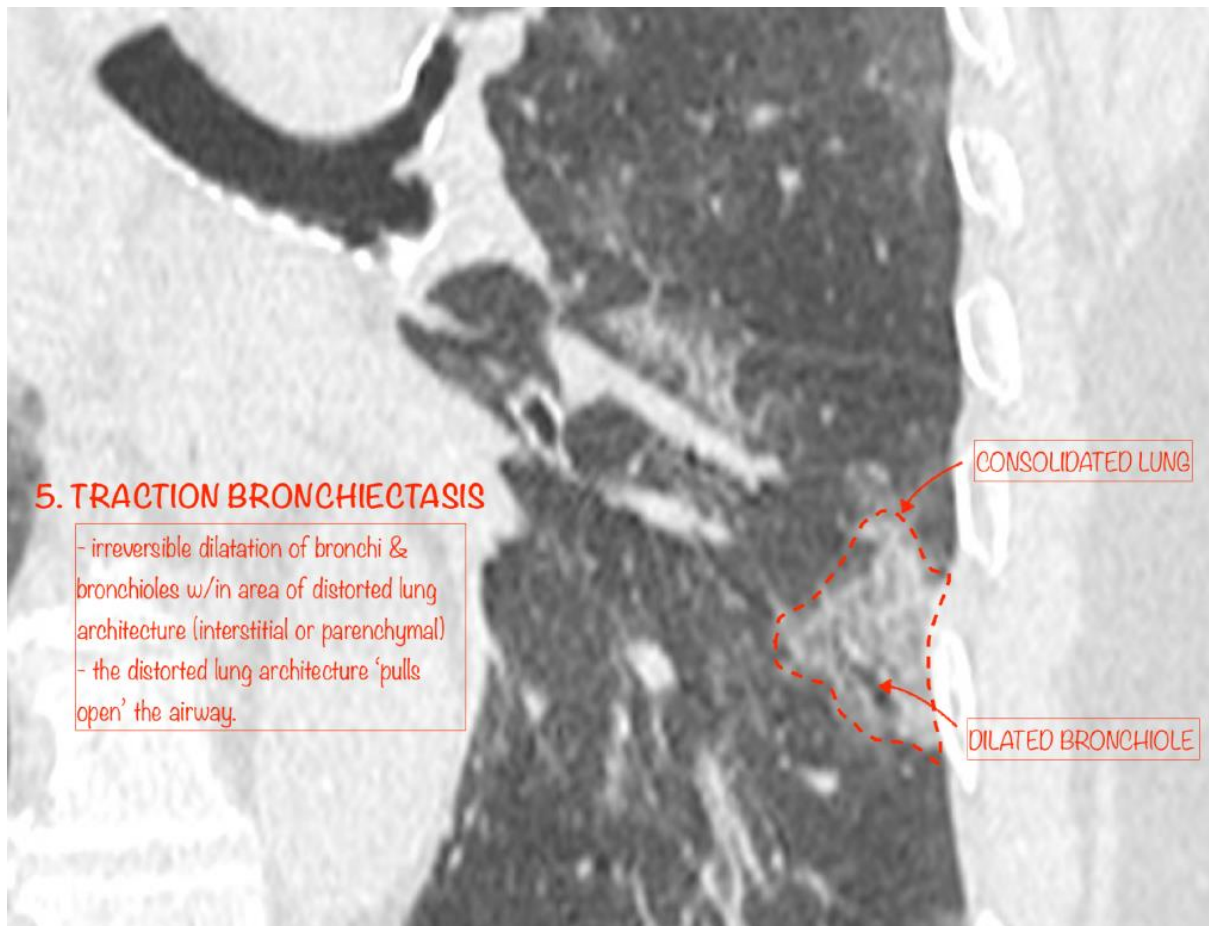
Case courtesy of Dr David Cuete
Radiopaedia.org <https://radiopaedia.org/>
From <https://radiopaedia.org/cases/30227>
rID: 30227

4. BRONCHOVASCULAR THICKENING

- widening of bronchiole & vascular structures
- non-specific descriptive term



Case courtesy of Dr Domenico Nicoletti
Radiopaedia.org <https://radiopaedia.org/>
From the case <https://radiopaedia.org/cases/74724>
rID: 74724



Case courtesy of Dr Fabio Macori
Radiopaedia.org <https://radiopaedia.org/>
From the case <https://radiopaedia.org/cases/74887>
rID: 74887

RESOURCES

COVID-19

- <https://radiopaedia.org/articles/covid-19-3?lang=us>
- <https://radiologyassistant.nl/chest/lk-jg-1#chest-radiograph>

FINDINGS

- <https://radiopaedia.org/articles/ground-glass-opacification-3?lang=us>
- https://radiopaedia.org/articles/crazy-paving?lang=us#image_list_item_321150
- https://radiopaedia.org/articles/air-space-opacification-1?lang=us#image_list_item_7780564
- <https://radiopaedia.org/articles/peribronchovascular-thickening?lang=us>
- <https://radiopaedia.org/articles/traction-bronchiectasis?lang=us>